

**JOHN LIVINGSTONE, MD**

**ABSTRACT TITLE:** A cadaveric study measuring femoral nerve tension during anterior total hip arthroplasty approach

### **BACKGROUND**

Femoral nerve palsy is a rare but devastating complication of anterior total hip arthroplasty. Its etiology is still unknown but several studies have suggested that anterior acetabular retractors may place the femoral nerve at increased risk.

### **QUESTIONS/PURPOSES**

The purpose of this study was to determine when the femoral nerve is under tension during anterior total hip arthroplasty. This study hypothesized that hip extension and traction places tension on the femoral nerve, offering an additional explanation for the development of femoral nerve palsy.

### **PATIENTS AND METHODS**

Five cadavers and six femoral nerves were utilized for this study. A spring device was secured across the transected femoral nerve as the hip was extended and pulled into traction with and without retractor placement. The change in spring length was used to determine femoral nerve tension.

Results: The average spring length changed +8.83mm with hip extension and +3.73mm with traction. Placement of the anterior acetabular retractor changed the average spring length by -0.7mm during traction and placement of the femoral retractor changed the average spring length by -1.15mm during extension.

Conclusions: Femoral nerve tension was greatest with hip extension followed by traction. Acetabular and femoral retractor placement decreased average femoral nerve tension in both traction and hip extension. This may be due to medialization of the femoral nerve by the retractors, reducing the overall distance traveled, and thereby reducing tension. Previous studies have found femoral nerve pressure to be greatest during anterior acetabular retractor placement. It is likely that both pressure and tension contribute to femoral nerve palsy in anterior total hip arthroplasty.

Clinical Relevance: Careful retractor placement, staying safely on anterior acetabular bone, and efficient femoral preparation to decrease time under hip extension and traction may help to minimize the risk of femoral nerve palsy.

Keywords: femoral, nerve, tension, anterior, THA, retractor

## **INTRODUCTION**

Femoral nerve palsy is an uncommon but devastating complication of anterior total hip arthroplasties. Studies have estimated the incidence to range from 0.21-1.1% [1, 2]. Despite this low incidence, nerve palsy is the most common reason for medical litigation for total hip arthroplasty[2, 5]. The etiology of femoral nerve palsy during anterior total hip arthroplasty is still unknown but several studies have suggested that anterior acetabular retractors may place the femoral nerve at an increased risk of being damaged. A study published in 2000 measured femoral nerve pressure with an electronic pressure transducer placed adjacent to the femoral nerve. This study demonstrated that in-vivo pressure around the femoral nerve increased significantly when the anterior acetabular retractor was placed during an anterior total hip arthroplasty. A significant increase in pressure was only found with anterior acetabular retractor placement and was not noted to change significantly during the rest of the procedure[6]. Another study from 2018 measured motor evoked potentials (MEPs) during direct anterior total hip arthroplasty and found that MEPs decreased to 54% of their preoperative amplitude when the anterior acetabular retractor was placed[3]. Lastly, a cadaveric study from 2019 found that the anterior acetabular retractor was closest to the femoral nerve when placed in the 90° orientation along the acetabulum[7]. These papers suggest that the anterior acetabular retractor places the femoral nerve at risk due to its proximity to the nerve, increased pressure around the nerve, and associated decrease in MEPs.

The hypothesis of this study was that extension of the hip during anterior total hip arthroplasty would lead to significant tension on the femoral nerve, similar to how hip flexion and knee extension can conversely affect the sciatic nerve[4]. With the femoral nerve running anteriorly over the brim of the pelvis, extension of the hip would intuitively tension the nerve during femoral preparation and may be another cause of femoral nerve palsy. It was hypothesized that both retractor placement and femur traction would increase femoral nerve tension as well.

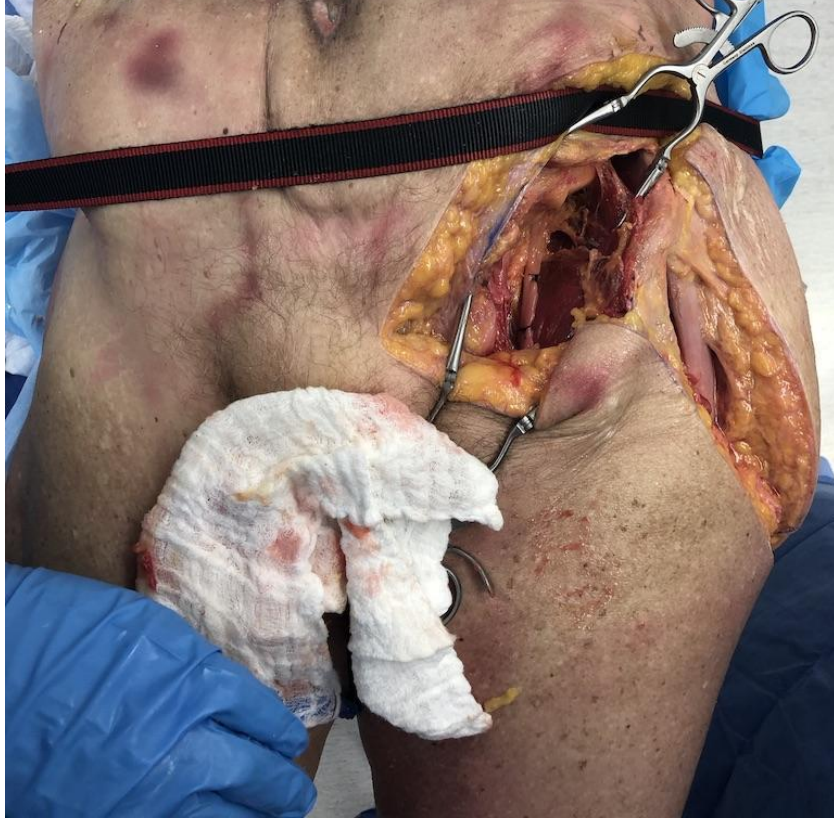## **MATERIALS AND METHODS**

Five fresh lower extremity cadavers were utilized for this study. The specimens were transected at various levels ranging from L1 to L3. A total of six femoral nerves were dissected from these five specimens.

The direct anterior (modified Hueter) approach was used to perform the proximal femur osteotomy as if an anterior total hip arthroplasty was going to be completed. The femoral nerve was identified through the ilioinguinal approach. The nerve was tracked distally as it crossed over the anterior brim of the pelvis (see Figure 1). A spring device was created to measure the tension placed on the femoral nerve. This device consisted of a clear acrylic tube, 9.4mm in diameter and about 70mm in length, with a thin 6mm diameter extension spring placed within the tube. The tube was then capped on either end with washers so that the spring would not fall out of the tube during testing. A 0-vicryl suture was tied to both ends of the spring and exited the tube through the central holes of the washers (See Figure 2). The femoral nerve was

transected about 3cm proximal to the anterior brim of the pelvis and the spring device was secured to both ends of the transected nerve proximal and distal to the spring device with the free ends of the suture. The device was pre-tensioned so that the spring was in some extension before manipulation (See Figure 3). The device was also ensured to be proximal to the anterior rim of the pelvis so that it would lie flat along the iliopsoas muscle. The length of the spring was measured with digital calipers in five different settings. The length of this spring was used as a proxy to estimate changes femoral nerve tension. The first setting was when the hip was in a neutral position while supine on the table with no retractors placed within the anterior total hip incision. The second setting was when axial traction was applied through the foot with the hip in a neutral position. The third setting was when axial traction was applied through the foot and the anterior acetabular retractors were placed to adequately visualize the acetabulum. During the first specimen exposure, 8kg of axial traction was required for adequate visualization of the acetabulum. This amount of axial traction was utilized for the remaining specimens for consistency. The fourth setting was when the hip was extended and externally rotated so that the cut end of the proximal femur could be adequately visualized. The fifth and final setting was when the hip was extended and externally rotated and the femoral retractor was placed around the posteromedial femur for femoral visualization. The foot was wrapped in a self-adherent elastic wrap and a mechanical spring scale was attached to the foot so a consistent amount of traction could be obtained with each specimen. Extension of the hip was obtained by placing the specimen on the edge of a table and supporting the contralateral leg on a mayo stand while the dissected leg was lowered into extension off of the table (See Figure 4).

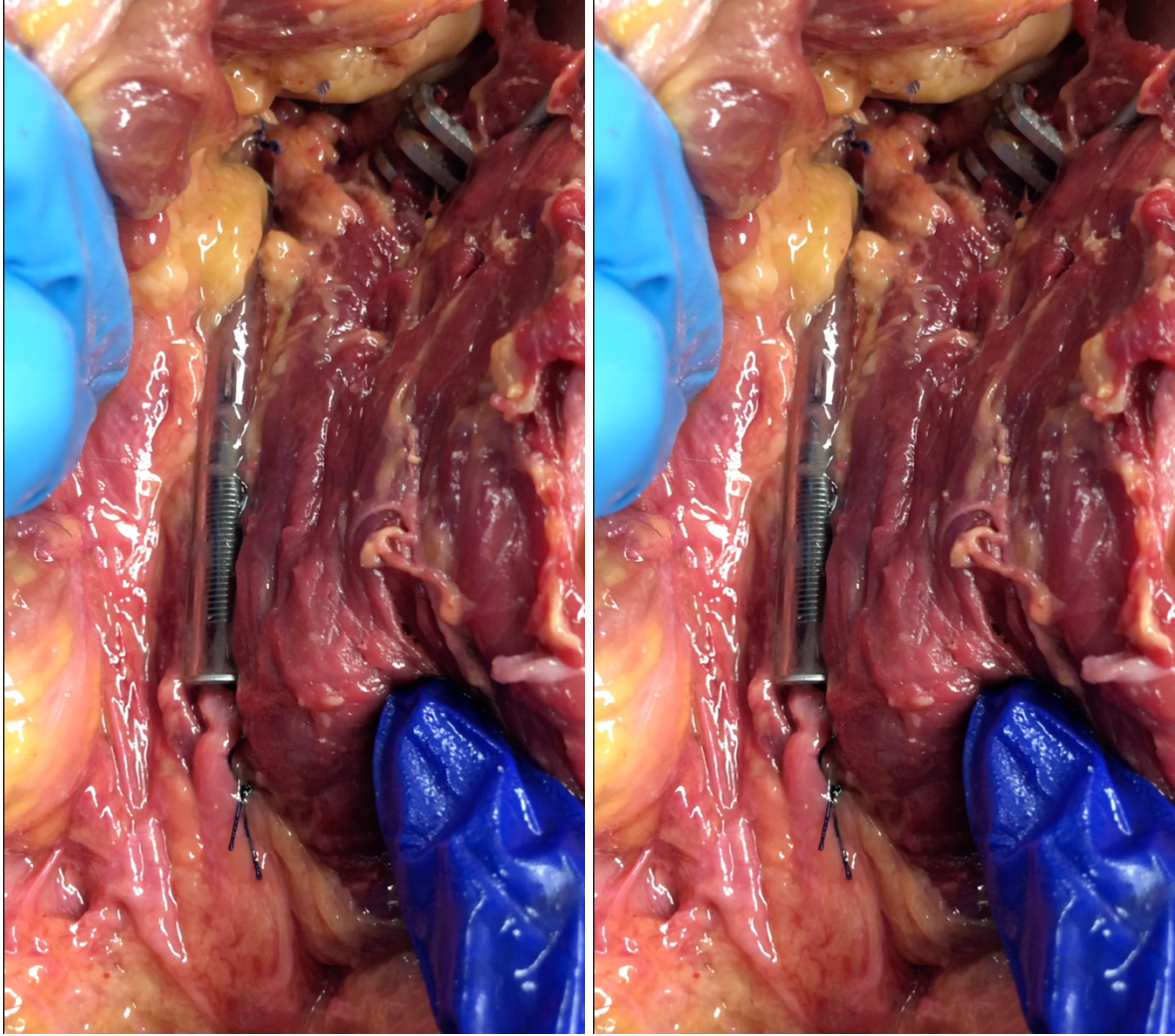
**Figure 1**



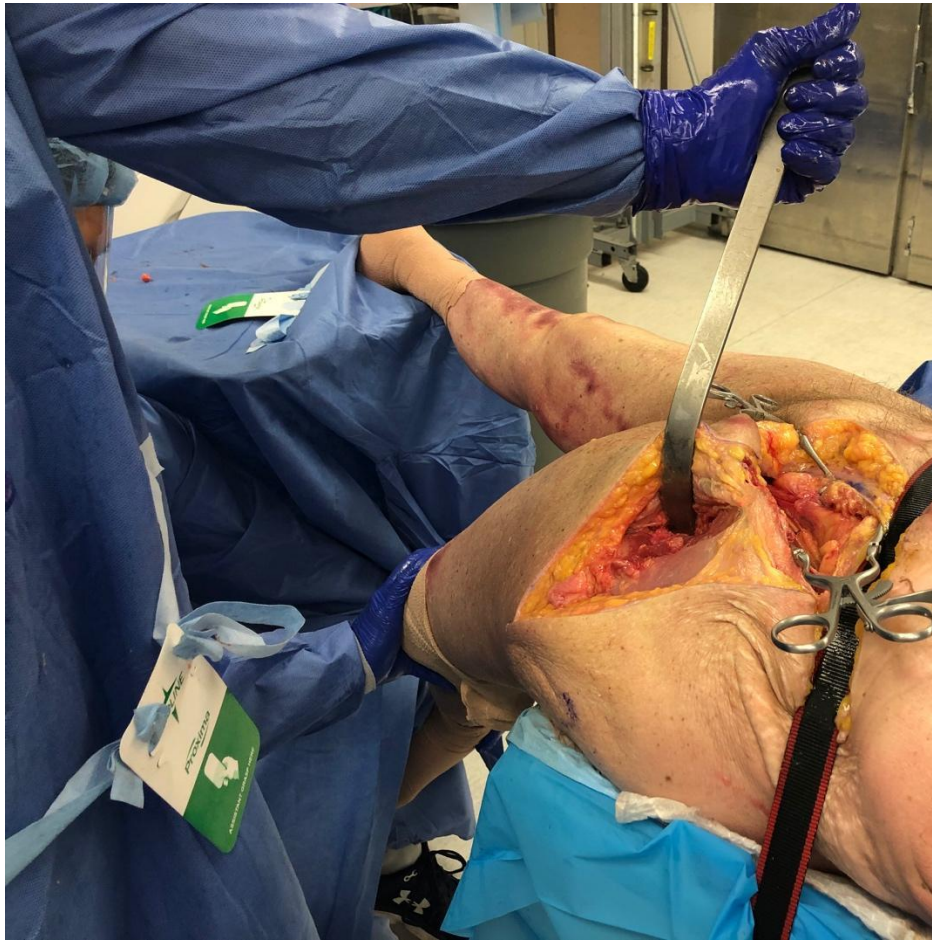**Figure 2**



**Figure 3**



**Figure 4**



**RESULTS**

A total of six femoral nerves from five cadaveric specimens were analyzed in this study. Specimens 4L and 4R were from the same cadaveric specimen with 4L representing the left femoral nerve and 4R representing the right femoral nerve. Traction was noted to increase spring length in all but one specimen where it had no effect. The average change in spring length after traction was +3.73mm. Placement of the anterior acetabular retractor after traction was applied was noted to decrease spring length in all but one specimen where it was noted to lengthen slightly by 0.3mm. The average change in spring length with the placement of the anterior acetabular retractor after traction was -0.7mm. Extension increased spring length in all specimens by an average of +8.83mm. The placement of the femoral retractor while in extension decreased spring length in four of six specimens with an average change in spring length of -1.15mm. See Tables 1-2 and Figure 5 for results.

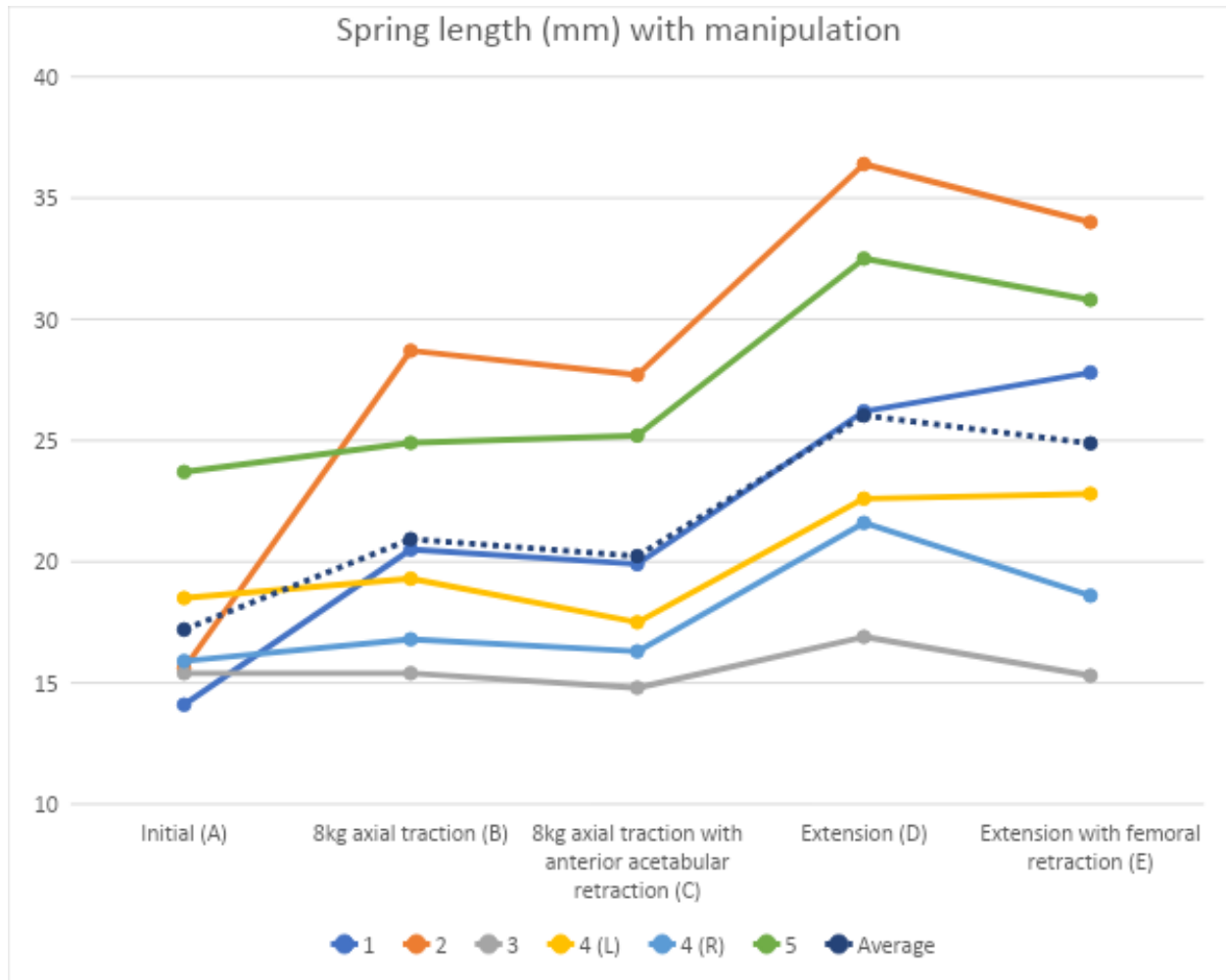
**Table 1:** Spring length (mm) with traction, extension, and/or placement of retractors

Specimen	Initial (A)	Traction (B)	Traction with anterior acetabular retraction (C)	Extension (D)	Extension with femoral retraction (E)
1	14.1	20.5	19.9	26.2	27.8
2	15.6	28.7	27.7	36.4	34.0
3	15.4	15.4	14.8	16.9	15.3
4 (L)	18.5	19.3	17.5	22.6	22.8
4 (R)	15.9	16.8	16.3	21.6	18.6
5	23.7	24.9	25.2	32.5	30.8
Average:	17.2	20.9	20.2	26.0	24.9

**Table 2:** Difference in spring length (mm) with traction, extension, and/or placement of retractors

Specimen	B-A	C-B	D-A	E-D
1	6.4	-0.6	12.1	1.6
2	13.1	-1	20.8	-2.4
3	0	-0.6	1.5	-1.6
4 (L)	0.8	-1.8	4.1	0.2
4 (R)	0.9	-0.5	5.7	-3
5	1.2	0.3	8.8	-1.7
Average:	3.73	-0.7	8.83	-1.15

**Figure 5**



**DISCUSSION**

Our study found that femoral nerve tension as measured by spring length was greatest while the hip was in extension during femoral preparation and that anterior acetabular retractors decreased femoral nerve tension. This is in contrast to a previous study which found that pressure around the femoral nerve increased most when the anterior acetabular retractors were placed. This study utilized an electronic pressure transducer to measure the pressure around the femoral nerve throughout an anterior total hip arthroplasty. The electronic pressure transducer was placed adjacent to the nerve while an anterior total hip arthroplasty was performed through a Watson-Jones anterolateral approach. This study did not find a significant change in pressure when the femur was prepared or during any other part of the surgery[6]. This difference in findings is likely due to the fact that our study measured tension and the previous study measured pressure. They estimated pressure on the femoral nerve by placing the pressure transducer adjacent to the nerve. During hip extension or traction, the femoral nerve likely does not experience any increase in pressure because it is not in a confined space

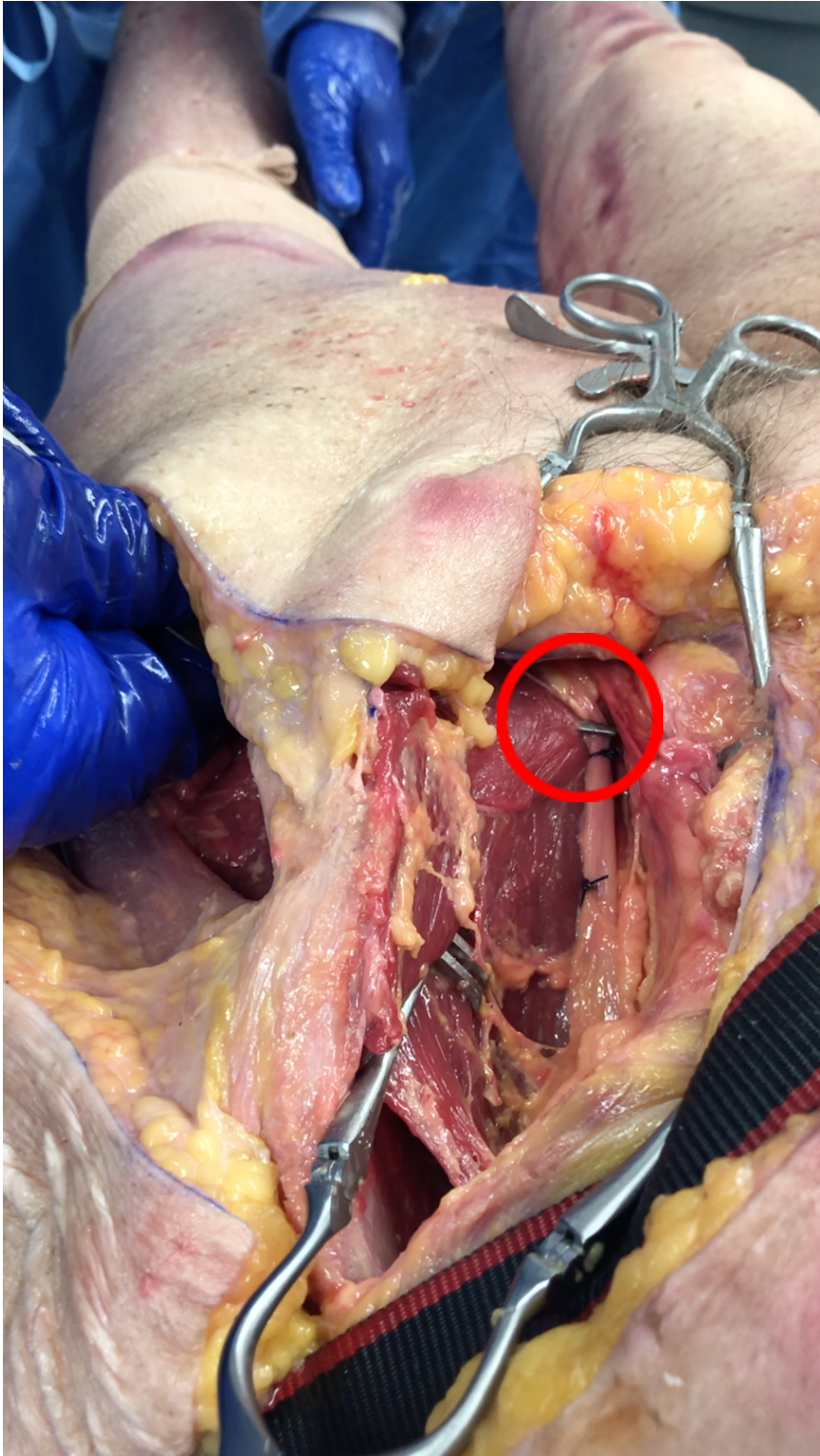


that would significantly decrease in volume with positional changes. If the pressure transducer was placed directly between the femoral nerve and the anterior brim of the pelvis, there may have been an increased pressure reading during hip extension as the femoral nerve was tensioned over the pressure transducer and the anterior brim of the pelvis. This was not likely done, however, since positioning the pressure transducer so intimately along the femoral nerve would likely place the femoral nerve at greater risk for damage or nerve palsy.

In the study by Ishimatsu, the use of MEPs also provided information in regard to the in-vivo function of the femoral nerve when anterior acetabular retractors were placed. This study noted that MEPs decreased to 54% of their preoperative amplitude when anterior acetabular retractors were placed. Unfortunately, MEPs were not measured during any other parts of the anterior total hip arthroplasty so it is unknown if MEPs decreased during hip extension or traction[3]. This study was also completed with the patient supine without the use of a traction table.

Our study demonstrated that on average, placement of retractors during both hip extension and traction decreased spring length. We also found that hip extension and traction increased spring length, with the former having the greatest effect. This implies that femoral nerve tension was increased with extension and traction and decreased with retractor placement. We expected nerve tension to increase with retractor placement since it has been shown to decrease MEPs and increase pressure adjacent to the nerve. One explanation for this finding is based on the anatomy of the femoral nerve. The femoral nerve naturally runs in a more lateral position over the iliopsoas muscle as it crosses over the anterior brim of the pelvis. When the anterior acetabular and femoral retractors were placed, the femoral nerve was noted to move medially as the retractor was brought up to visualize the acetabulum or the femur. It is possible that by moving the nerve more medially it can then take a more direct and shorter path, reducing the tension on the nerve. One cannot conclude, however, that extension and traction are more likely to lead to a femoral nerve palsy than anterior acetabular retractor placement. Nerve palsies may occur through either compression or tension of the nerve. Both of these forces may be responsible for a femoral nerve palsy with anterior acetabular retractors placing the most pressure on the nerve while extension and traction create the most tension. Similar to the study by Yoshino et. al, we also noted the close proximity of the anterior acetabular retractors to the femoral nerve[7]. We noted that if the retractor doesn't stay on bone, it could easily puncture through the iliopsoas and be placed directly on the femoral nerve (See Figure 6).

Figure 6



The purpose of creating the spring device used for this study was to have a direct measurement of the tension of the femoral nerve rather than an indirect measurement of pressure seen in the study by Slater et. al[6]. We initially attempted to visualize the tension of the femoral nerve by placing two sutures in the femoral nerve and measuring the distance between these sutures as the leg was pulled into traction or extension with and without retractors. The distance between the sutures did not change with these maneuvers. This implied that the femoral nerve was likely experiencing tension but its elasticity was not visually appreciated. An analogy to this would be how a steel cable can be under significant tension but there is no appreciable change in its length. By transecting the femoral nerve and securing our spring device between its cut ends, the tension can be more easily visualized. There are several limitations to the use of the spring device, however. First, the device needed to be placed so that it wouldn't limit or alter the normal path of the femoral nerve. This was theoretically accomplished by keeping the device small and placing it over the iliopsoas before the femoral nerve crosses over the anterior brim of the pelvis. This would allow the nerve to glide and stretch in an anatomic position over the anterior brim of the pelvis. Second, the spring length needed to be measured from outside of the acrylic tubing which meant that the calipers had to be visually compared to the spring itself rather than by making direct physical contact with the spring. It would be ideal if the spring itself could make contact with the calipers for more accurate measurement but the acrylic tube around the spring was needed to decrease any friction that the spring may have encountered if it was placed directly into the soft tissues and to prevent debris from building up within the spring which would have prevented it from compressing fully. The spring was pre-tensioned in its initial position to remove any slack from the femoral nerve prior to applying traction, extension, and/or retractors. The amount of pre-tensioning was not consistent amongst specimens but this should not affect the results of this study since the change in length of a spring is linearly related to the force applied based on Hooke's law. The springs were never noted to deform and were kept well within their elastic region with testing.

There are other limitations to our study as well. The anterior acetabular and femoral retractors were placed in similar positions in every specimen but the amount of force applied to the retractor was not controlled. The force applied to the retractor was kept to a minimum by only pulling on the retractor enough for adequate visualization of the acetabulum or femur. This was felt to be acceptable since this is a realistic amount of force that would be used during an actual anterior total hip arthroplasty. This study was also limited by a small number of specimens.

Future studies are needed to evaluate the effects of extension and traction on the femoral nerve. Another study measuring MEPs throughout the entire anterior total hip arthroplasty rather than just before and after anterior acetabular retractor placement may provide further insight into the effects of positioning on the femoral nerve.

## **CONCLUSION**

This study demonstrated that femoral nerve tension as measured by spring length increases with hip extension during anterior total hip arthroplasty. Tension on the nerve was also increased during axial traction but to a lesser extent. The tension on the femoral nerve was noted to decrease when both anterior acetabular and femoral retractors were placed. This may

be due to the medialization of the femoral nerve which may decrease its overall length traveled, thereby reducing its tension. The findings of this study in combination with previous studies suggest that the femoral nerve likely experiences maximum compressive forces with anterior acetabular retractor placement and maximum tension during hip extension and traction. Both of these forces may contribute to femoral nerve palsies in anterior total hip arthroplasty. Unfortunately, hip extension, traction, and retractor placement are all necessary components of a safe and successful anterior total hip arthroplasty with current total hip arthroplasty technology. Therefore, careful retractor placement, staying safely on anterior acetabular bone, and efficient femoral preparation to decrease time under hip extension and traction may help to minimize the risk of femoral nerve palsy.

1. Fleischman AN, Rothman RH, Parvizi J. Femoral Nerve Palsy Following Total Hip Arthroplasty: Incidence and Course of Recovery. *J Arthroplasty*. 2018;33:1194-1199. Available at: <https://doi.org/10.1016/j.arth.2017.10.050>.
2. Hoshino C, Koga D, Koyano G, Yamauchi Y, Sakai T, Okawa A, Jinno T. Femoral nerve palsy following primary total hip arthroplasty with the direct anterior approach. *PLoS One*. 2019;14:1-12.
3. Ishimatsu T, Kinoshita K, Nishio J, Tanaka J, Ishii S, Yamamoto T. Motor-evoked potential analysis of femoral nerve status during the direct anterior approach for total hip arthroplasty. *J Bone Jt Surg - Am Vol*. 2018;100:572-577.
4. Letournel E, Judet R. *Fractures of the Acetabulum*. (Elson RA, ed.). Berlin, Heidelberg: Springer Berlin Heidelberg; 1981. Available at: <http://link.springer.com/10.1007/978-3-662-02325-9> [Accessed January 19, 2021].
5. Samuel LT, Sultan AA, Rabin JM, Surace PA, Yao B, Moskal JT, Mont MA. Medical Malpractice Litigation Following Primary Total Joint Arthroplasty: A Comprehensive, Nationwide Analysis of the Past Decade. *J Arthroplasty*. 2019;34:S102-S107. Available at: <https://doi.org/10.1016/j.arth.2019.02.066>.
6. Slater N, Singh R, Senasinghe N, Gore R, Goroszeniuk T, James D. Pressure monitoring of the femoral nerve during total hip replacement: An explanation for iatrogenic palsy. *J R Coll Surg Edinb*. 2000;45:231-233.
7. Yoshino K, Nakamura J, Hagiwara S, Suzuki T, Kawasaki Y, Ohtori S. Anatomical Implications Regarding Femoral Nerve Palsy During a Direct Anterior Approach to Total Hip Arthroplasty. *J Bone Jt Surg*. 2020;102:137-142. Available at: <http://journals.lww.com/10.2106/JBJS.19.00667>.

## **FIGURE LEGEND**

Figure 1: Exposure of the left femoral nerve through the ilioinguinal approach. A direct anterior (modified Hueter) approach was used to perform a left proximal femur osteotomy. Two sutures were placed through the intact femoral nerve for identification.

Figure 2: Spring device consisting of a thin spring inside a clear acrylic tube with washers on either end of the tube. The spring is tied to 0-vicryl suture on either end.

Figure 3: The spring device is secured to either end of the transected femoral nerve. The left photo demonstrates the initial position without retractor placement, extension, or traction. Note that the spring is pre-tensioned and is not in its resting state. The right photo demonstrates traction without retractor placement. Orientation: medial left, proximal up.

Figure 4: The specimen can be seen here with the hip in extension and external rotation with the femoral retractor in place. The specimen was positioned on the edge of the table with the contralateral leg on a mayo stand. A ratcheting strap was used to secure the specimen to the table.

Figure 5: A graphical representation of spring length (mm) changing with traction, extension, and/or retractor placement

Figure 6: This photo demonstrates how the anterior acetabular retractor, circled in red, can be mistakenly placed directly over the femoral nerve if the retractor is not kept on the acetabulum.